

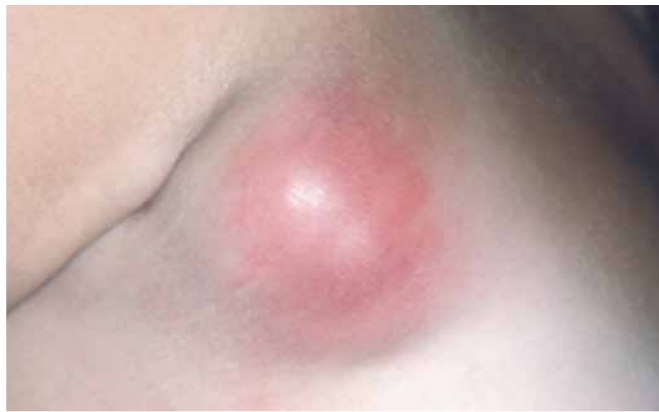## Bartonella spp.

High *Bartonella henselae* prevalence is reported in cats (up to 93% seroprevalence in some cat colonies<sup>[17]</sup>). The bacteria inhabit red blood cells, which are ingested by the flea during the blood meal and survive in its gut. *B. henselae* DNA is detected in both fleas and their faeces for the entire life span of the arthropod, starting 24 hours after the blood meal<sup>[18]</sup>.

*B. henselae* is transmitted among cats by *Ctenocephalides felis* fleas or by contaminated flea faeces deposited on the skin and ending up under the cat's claws due to grooming.

Naturally infected cats are usually asymptomatic carriers or show only mild transient clinical signs (e.g., fever), except cats co-infected with FIV that may exhibit lymph node swelling, stomatitis, gingivitis, uveitis or even **endocarditis**.

*B. henselae* infection of humans is mainly associated with **cat scratches**, hence the name 'cat-scratch disease' given to this zoonosis. In immunocompetent persons, the symptoms usually consist in self-limiting regional lymphadenopathy developing after a primary popular lesion and lasting for a few weeks to several months.



Inflammatory axillary lymphadenopathy following a cat scratch (Courtesy from Dr M. Giladi, Tel Aviv Medical Center).

On the other hand, in immunocompromised people more severe forms may occur, such as peliosis hepatis, bacillary angiomatosis, bacterial endocarditis and several other inflammatory syndromes such as polyarthritis.

## IMPORTANCE OF THE PREVENTION OF CAT ZONOTIC PARASITE INFESTATIONS IN SUPPORT OF ONE HEALTH

The prevention of zoonotic parasitic diseases involves **controlling parasite infestations in cats to reduce or interrupt the transmission to people**. This may be more or less achievable, depending on the parasite, as it is much more difficult to prevent a cat from being exposed to parasite infestations through preying on rodents and birds or roaming around, than any other pet animal.

Preventative measures in cats include a **regular treatment against both internal and external parasites** based on the cat lifestyle and risk exposure, as well as avoiding raw meat in their diet.

**Hygiene rules** such as washing hands regularly, cleaning fruits and vegetables, eating well cooked meat and cleaning the cat litter tray daily, **are also key** to reduce the risk of parasitic zoonoses in humans.

## REFERENCES

1. Spada E. et al. (2013). Prevalence of faecal-borne parasites in colony stray cats in northern Italy. *Journal of Feline Medicine and Surgery* 15(8) 672–677.
2. Takeuchi-Storm, N. et al. (2015). Gastrointestinal parasites of cats in Denmark assessed by necropsy and concentration McMaster technique. *Veterinary Parasitology*, 214(3), 327–332
3. Loftin, C. M. et al. (2019). Prevalence of endoparasites in northern Mississippi shelter cats. *Veterinary Parasitology: Regional Studies and Reports*, 18, 100322.
4. Symeonidou I. et al. (2018). Feline gastrointestinal parasitism in Greece: emergent zoonotic species and associated risk factors. *Parasites & Vectors*, 11(1), 227.
5. Nagamori Y. et al. (2018). Faecal survey of parasites in free-roaming cats in north central Oklahoma, United States. *Veterinary Parasitology: Regional Studies and Reports*, 14 (2018) 50–53.
6. Nagamori Y. et al. (2020). Retrospective survey of parasitism identified in faeces of client-owned cats in North America from 2007 through 2018. *Veterinary Parasitology* 277-109008.
7. Beugnet F. et al. (2014). Parasites of domestic owned cats in Europe: Co-infestations and risk factors. *Parasites & Vectors*, 7, 291.
8. Otero D. et al. (2018). Environmental contamination with *Toxocara* spp. eggs in public parks and playground sandpits of Greater Lisbon, Portugal. *Journal of Infection and Public Health* 11, 94–98.
9. Magnaval J.F. et al. (2001). Highlights of human toxocarosis. *Korean Journal of Parasitology* 39,1–11.

10. Inpankaew T. et al. (2021) Prevalence of toxoplasmosis in semi domesticated and pet cats within and around Bangkok, Thailand. *BMC Veterinary Research* 17:252
11. Must K. et al. (2017). *Toxoplasma gondii* seroprevalence varies by cat breed. *PLoS ONE* 12(9): e0184659.
12. Montoya JG, Liesenfeld O. (2004). Toxoplasmosis. *Lancet* 363:1965– 1976.
13. Beugnet F. et al. (2014). Occurrence of *Dipylidium caninum* in fleas from client-owned cats and dogs in Europe using a new PCR detection assay. *Veterinary Parasitology* 205, 300–306.
14. Ramana KV. et al. (2011). Human dipylidiasis: a case report of *Dipylidium caninum* infection from Karimnagar. *Online Journal of Health and Allied Sciences*; 10 (2).
15. García-Agudo L. et al. (2014). *Dipylidium caninum* infection in an infant: a rare case report and literature review. *Asian Pacific Journal of Tropical Biomedicine*; 4 S565-S567.
16. Taylor T, Zitzmann MB. (2011). *Dipylidium caninum* in a 4-month-old male. *Clinical Laboratory Science*; 24: 212-214.
17. Pearce, L.K. et al. (2006). Prevalence of *Bartonella henselae* antibodies in serum of cats with and without clinical signs of central nervous system disease. *Journal of Feline Medicine and Surgery* 8, 315e320.
18. Bouhsira E. et al. (2013). *Ctenocephalides felis* an in vitro potential vector for five *Bartonella* species. *Comparative Immunology, Microbiology and Infectious Diseases*; 36: 105-111.



Serviceplan | Crédits photos : iStock, Boehringer Ingelheim.

# TECHNICAL BULLETIN



n°4

## TOP 3 ZONOTIC PARASITES IN CATS

The relationship between cats and their owners plays a recognised role in helping maintain the mental and physical health of humans, yet it has the potential for causing illness, if the cat is not under parasite control. For instance, **a study in a population of stray - therefore untreated - cats has shown that endoparasites with zoonotic potential were present in 49.6% of individuals<sup>[1]</sup>, *Toxocara cati*, the cat roundworm and *Toxoplasma gondii* are part of the 'top 3' zoonotic parasites either based on their frequency in cats, or on the potential severity of the human diseases. **Cat fleas must be considered in this ranking, both as zoonotic parasites and due to the role they can play in the transmission of zoonotic agents.****

### TOXOCARA CATI



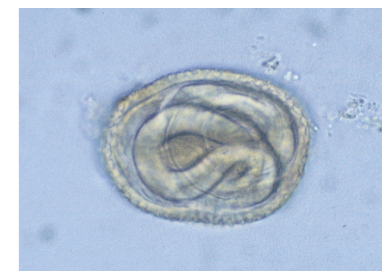*Toxocara cati* is one of the most common parasitic worms found in cats worldwide, with prevalence ranging from less than 10 to more than 84% in various coprological and postmortem surveys, depending on the geography, age and cat lifestyle, the mean being around 20% in owned cats.<sup>[2-7]</sup>

Female worms live in the cat upper digestive tract and may produce up to 200,000 eggs per day.

*Toxocara cati* eggs are very resistant in the environment and can persist up to several years even at temperatures ranging from -10°C to 45°C. They fear neither drought nor liquid environments and retain their ability to infest a new animal for 2 to 5 years.

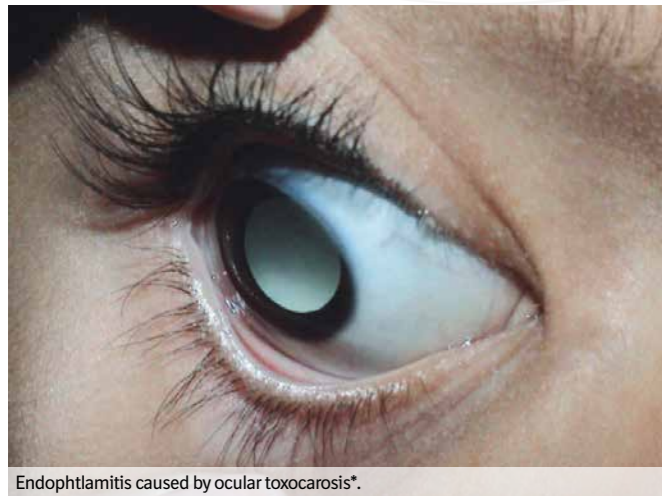

**TOXOCARA SP. EGGS RECOVERED PER HUNDRED GRAMS OF COLLECTED SOIL<sup>[8]</sup>**



*Toxocara* infective egg.





Endophthalmitis caused by ocular toxocarosis\*.

system move between tissues. The resulting inflammation can cause various symptoms, depending on their location.

- **Covert toxocarosis represents the majority of cases.** It is usually benign, most patients being **asymptomatic or showing non-specific aches and pains**, weakness, and nausea.
- **A large number of larvae** can cause a condition known as **visceral larva migrans**, resulting in an **impairment of the general health** status including weight loss and fever along with asthmatic cough, wheezing, and generalised lymphadenopathy.
- More severe forms may occur:

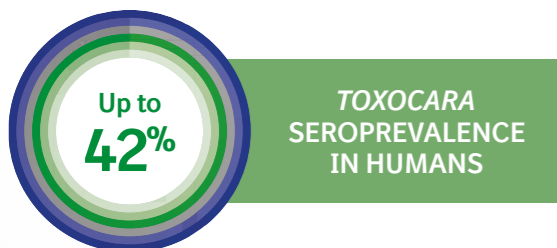- **Ocular larva migrans** is due to the presence of a larva in the eye wall or in close proximity. The induced chronic inflammation and immunological response cause **uveitis or retinitis leading to vision loss**. The disease is more frequent in toddlers, children, teenagers and young adults.
- **Nervous toxocarosis**, linked to larvae reaching the central nervous system, is very rare. It causes non-specific illnesses such as meningitis, meningoencephalitis, **persistent headaches, seizures and psychosis**.

Infestations are assumed to be caused by environments heavily contaminated with *Toxocara* eggs (as parks, playgrounds, sandboxes and cat's household) and more frequent in children because of the closer contact with contaminated soil in yards and sandpits, eating dirt and lack of hygiene.



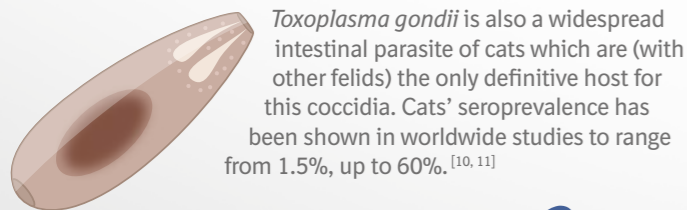
Clinical signs in cats are only present in cases of high burdens of worms. They may include potbelly, diarrhoea, irregular appetite, poor coat and failure to thrive. *Toxocara cati* has also been described as a possible cause for pneumonia with coughing, following pulmonary migration of L4 larvae in cats.

*Toxocara cati* is recognised as a causative agent of human disease. Epidemiological surveys have shown that human larval toxocarosis is one of the most common helminth infestations in the world. In the Western countries, the seroprevalence varies between 2% and 5% in urban areas, reaches 15%–20% in semi-rural zones such as residential outskirts of large cities, and peaks at 35%–42% in rural areas<sup>[9]</sup>.



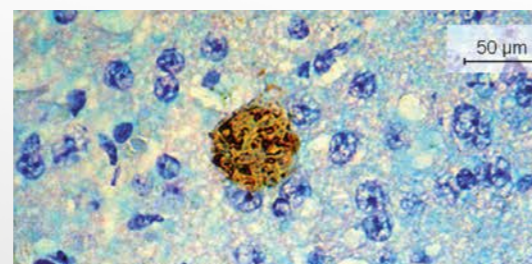
After accidental ingestion of infective eggs, the larvae hatch, penetrate across the gut and are transported to the liver, lungs and virtually any organ. Some larvae that are not killed by the immune

## TOXOPLASMA GONDII

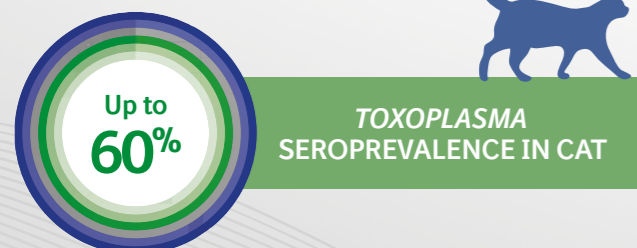

*Toxoplasma gondii* is also a widespread intestinal parasite of cats which are (with other felids) the only definitive host for this coccidia. Cats' seroprevalence has been shown in worldwide studies to range from 1.5%, up to 60%.<sup>[10, 11]</sup>

After the primary infection, cats shed millions of oocysts in their faeces. Once sporulated, oocysts are capable to infect all warm-blooded animals, including humans. They remain viable for long periods of time in water, also resisting to freezing and moderately high water temperatures.



Cyst with bradyzoites. H&E staining. Brain histology.



**In cats, the main clinical entity is the toxoplasmic coccidiosis** and most cats do not show any signs, but a mild diarrhoea can be observed. In non-immune individuals, toxoplasmosis can occur but here again the disease is mainly asymptomatic or limited to fever and lymph nodes enlargement.

*Toxoplasma gondii* is recognised as the agent of a widespread zoonosis: it is generally assumed that approximately 25 to 30%



of the world's human population is infected by *Toxoplasma*. The prevalence varies widely between countries, from 10 to 80%.<sup>[12]</sup>

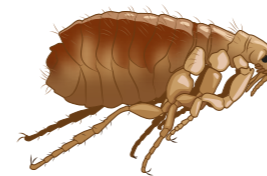
**People usually become infected through the ingestion of oocyst in contaminated soil and water derived from the environment**, or present on unwashed fruits and veggies. But they can also be contaminated by ingesting tissue cysts in undercooked meat. Direct contamination from feline faeces (litter) is rare.

**In humans, healthy adults generally have a low risk of developing severe toxoplasmosis** after infection: primary acquired infection is asymptomatic in more than 80% of cases of immunocompetent subjects in European countries or North America<sup>[12]</sup>. In other cases, fever or cervical lymphadenopathy, sometimes associated with myalgia, asthenia, or other nonspecific clinical signs can be observed.

However, immunocompromised individuals can suffer from severe local (mostly ocular or cerebral) or generalised toxoplasmosis, that may be life-threatening.

**Congenital toxoplasmosis occurs when a non-immune woman gets the primary infection during pregnancy.** An early foetal infection may result in abortion, toxoplasmic macrocephaly, hydrocephaly, ocular and nervous problems. The foetal infection during the last two trimesters of the pregnancy may lead to fatal visceral forms or syndroms appearing after birth (e.g., chorioretinitis, developmental delay).

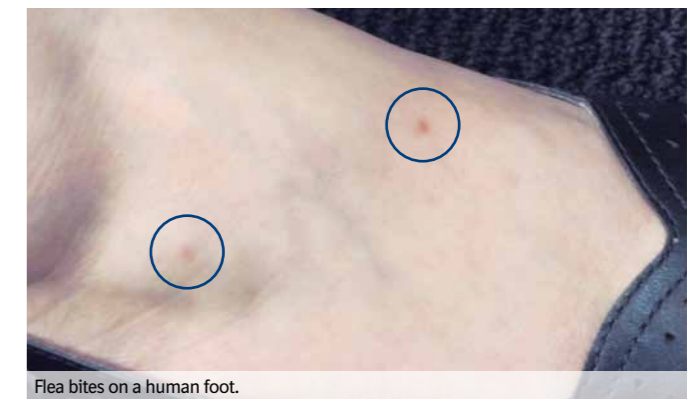## CTENOCEPHALIDES FELIS FLEAS AND FLEA-BORNE PATHOGENS



The cat flea, *Ctenocephalides felis*, is an ectoparasite of overwhelming importance due to its high prevalence worldwide and the burden it represents for pets including cats, being responsible for pruritus, skin lesions and even allergic reactions.

*C. felis* is quite aggressive, non-specific and feeds on the blood of any mammal available, including humans. They are not only zoonotic parasites by essence, but they are also a source of human contamination by zoonotic agents, such as the cestode *Dipylidium caninum* and most frequently the bacterium *Bartonella henselae*.

*Dipylidium caninum* is a common intestinal tapeworm of cats, acquired through the ingestion of the intermediate hosts, *Ctenocephalides felis* fleas (or more rarely, lice, *Felicola subrostratus*) containing the metacestode infective stage

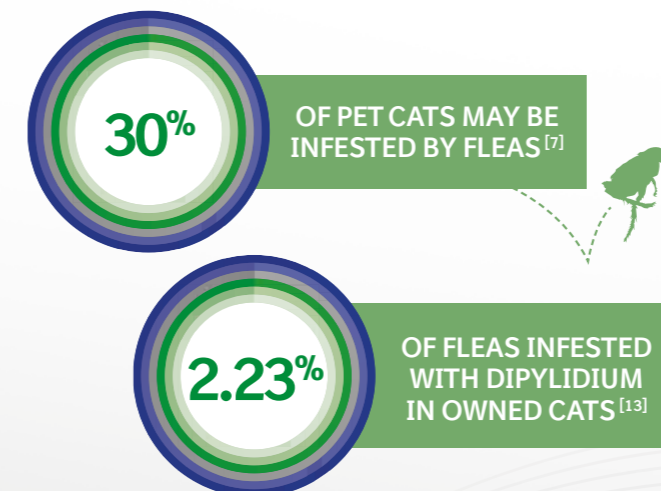


Flea bites on a human foot.

during grooming. In cats, the adult tapeworms are poorly pathogenic, and many can be tolerated without any significant clinical effect. The shed segments may cause some discomfort as they crawl actively from the anus, and a common sign of infestation in pets is excessive grooming of the perineum.

**Humans may host this cestode if they happen to ingest an infested cat flea.** The risk of *D. caninum* infestation in adults is very low, but toddlers and young children are at higher risk of acquiring it, due to their proximity with pets.

Infested humans are often asymptomatic but anal pruritus, diarrhea, mild abdominal pain, decrease in appetite, indigestion, and gastrointestinal tract disturbances may be seen<sup>[14, 15]</sup>. Occasionally, urticaria, eosinophilia, psychologic irritability, slight reduction in weight gain, and intestinal obstruction have also been described<sup>[16]</sup>. In terms of frequency, the most common sign detected is active proglottids appearing in the perianal area, diaper, or stool. Then, anal pruritus, diarrhea, abdominal pain, and loss of appetite follow.



\* Picture from the article: Leukocoria and the red reflex test. Yassuda Tamura M. Y., Teixeira L.F. Einstein. 2009; 7(3 Pt 1):376-82